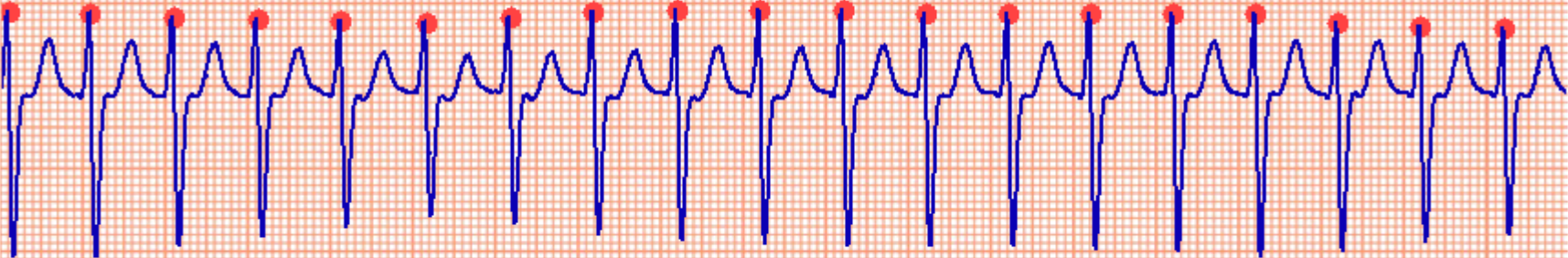


Slow-Fast Nodal Reentry Tachycardia



25 mm/sec